

CLINICAL REVIEW 113

Hypopituitarism Secondary to Head Trauma

SALVATORE BENVENGA, ALFREDO CAMPENNI, ROSARIA M. RUGGERI, AND
FRANCESCO TRIMARCHI

*Cattedra e Divisione di Endocrinologia, University of Messina School of Medicine,
98125 Messina, Italy*

In a classic article published in this journal more than 50 yr ago, Escamilla and Lissner (1) reported that head trauma accounted for hypopituitarism in only 4 of 595 patients (0.7%). In the following 19 yr, Altman and Pruzanski (2) collected 15 additional cases of posthead trauma hypopituitarism (PHTH) from the international literature. In the subsequent 25 yr, Edwards and Clark (3) collected 34 new cases, so that their review concerned a total of 53 cases. No subsequent review on PHTH has appeared thereafter.

After our initial observation of the first genuine case of posttraumatic isolated hypogonadotropic hypogonadism (4), namely the posttraumatic selective damage of the gonadotrophs, we became alerted about PHTH. Our experience with this patient (4) proved to be fruitful, because it helped us to diagnose PHTH—rather than “idiopathic” hypopituitarism—in subsequent patients (5). We learned, in fact, that head trauma can be minor and had occurred several years earlier, so that the patient may lose recollection of it. Thus, we learned to help the patient (and his or her relatives) to recollect these traumas.

In addition to screening the literature from 1986 through 1998, we also screened the years 1970–1985 to ensure that Edwards and Clark (3) had not missed some cases, as indeed they did (6–13). Thus, we bring the total of PHTH cases to 367, namely 314 more than the 53 cases reviewed by Edwards and Clark (3). The 314 cases (4–26) include our own 15 cases (Refs. 4 and 5 and our unpublished data), but not the 11 cases reported by Cytowic and Smith (27) in a letter to the editor because of the selectivity of their series (all women who had developed amenorrhea) and the lack of hormone measurements. We warn the reader that not all the articles report all the relevant parameters that we will review, so that the resulting prevalences have different denominators.

The aim of the present review is to assess the epidemiological, clinical, and endocrinological features of hypopituitarism following head trauma.

Received August 7, 1999. Revision received December 14, 1999. Accepted December 20, 1999.

Address correspondence and requests for reprints to: Salvatore Benvenega, M.D., Cattedra e Divisione di Endocrinologia, Policlinico Universitario, Padiglione H, 4° piano, 98125 Messina, Italy.

Generalities

PHTH is predominantly a medical problem of the young man because the male to female ratio is 5:1 (Fig. 1, *top*), and in about 60% of the cases head trauma had occurred at the age of 11–29 yr (Fig. 1, *middle*). The single decade most at risk is the third. Thereafter, the frequency of PHTH declines progressively. Even though the majority of patients develop symptoms of hypopituitarism relatively early (Fig. 1, *bottom*), PHTH may become clinically evident at any time after the accident, and 15% of patients are diagnosed 5 or more years after the trauma. Particularly impressive are two patients in whom posttraumatic central hypothyroidism was diagnosed 36 and 46 yr after head trauma (3, 22). Of 15 of our patients (4, 5) with PHTH, head trauma had occurred more than 10 yr earlier in 8 (Table 1).

The type of trauma is diverse, but in about three fourths of the cases, it is represented by road accidents (Fig. 2A). In our series (Table 1), road accidents accounted for half of the cases. Although it is unlikely that a road accident and the following hospitalization are forgotten by the patient, this happened to a number of our patients. For instance, our first PHTH patient (case 15 in Table 1), who sought our evaluation for erectile dysfunction, had had a motorcycle accident 8 yr before our observation (4). He did not mention this accident in the first history he gave us, even though he had been hospitalized at the Neurosurgery Institute of our University Hospital (4). For this relatively poorly educated 26-yr-old man, to ask for “accidents or surgical interventions at the head” was not sufficient to let him recollect the trauma he had suffered 8 yr before. This required, when we reinterviewed him, to explicitly ask for car or motorcycle or bicycle or truck or bus accidents. Even after these explicit specifications, it was his wife who answered the question. Similarly, it was during reevaluation of the first history and in the presence of the relatives that nine of our patients were reminded of the trauma. Because most of our patients—two of whom are physicians!—had not been hospitalized for the head traumas (Table 1), this fact clearly contributed to their forgetfulness.

Head trauma may or may not be complicated by skull fractures with essentially the same frequency (Fig. 2B), whereas a more or less profound loss of consciousness occurs almost always (Fig. 2C). In most of the cases, coma lasts for

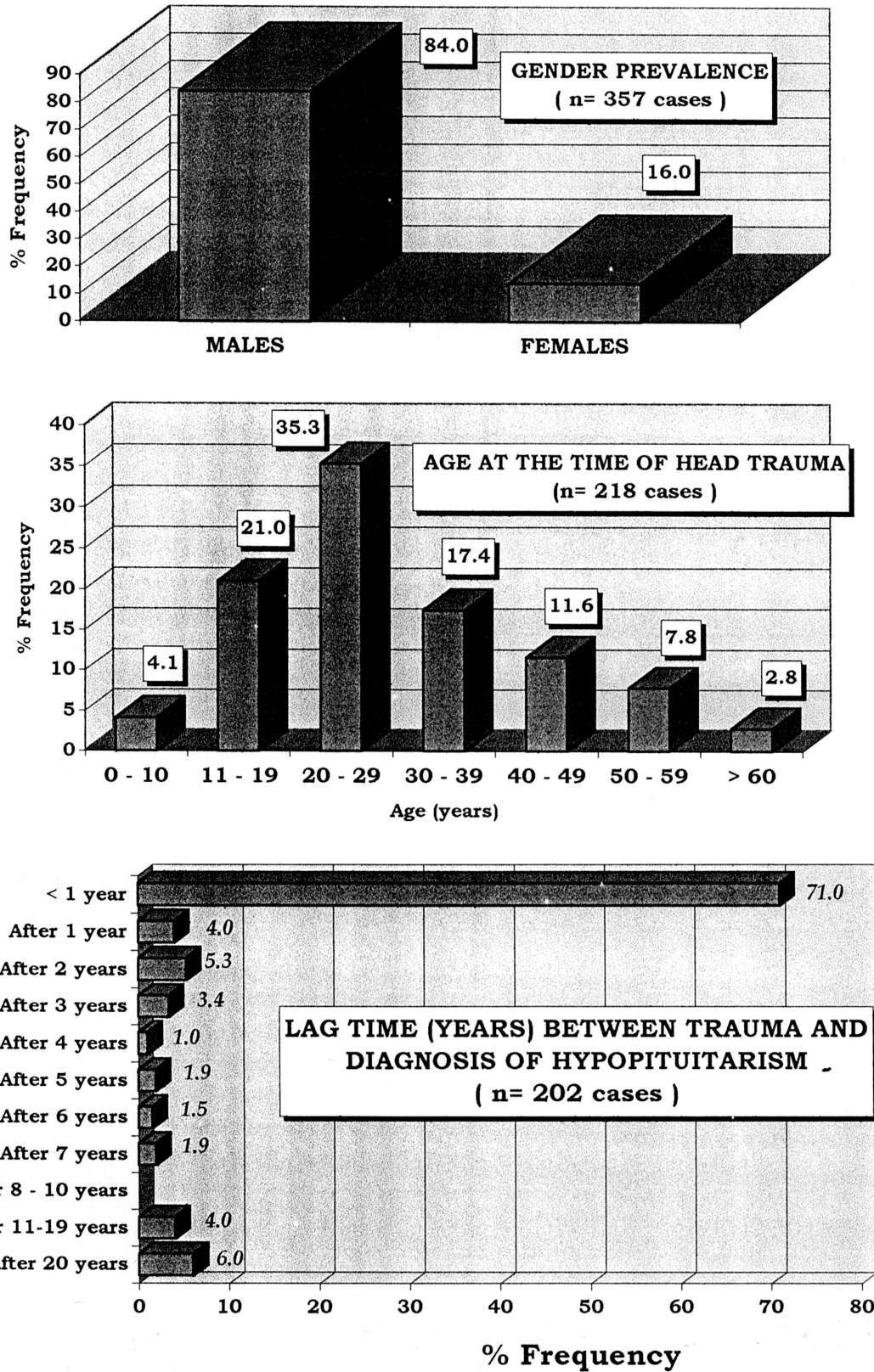


FIG. 1. Prevalence of gender (top), age (middle), and lag-time between trauma and diagnosis (bottom) in posttraumatic hypopituitarism.

TABLE 1. Summary of the main clinical, hormonal and pituitary imaging data in 15 patients with posttraumatic hypopituitarism

Case no. and sex	Age (yr) ^a	Cause of head trauma ^b	Hospitalization	Deficient hormones ^c	Pituitary imaging ^d
1. F	30/47	Diving	Yes	FSH, LH, TSH	Refused for claustrophobia
2. F	41/47	Fall from stairs	Yes	TSH	Areas of hypodensity
3. F	33/50	Car accident	Yes	TSH, GH	Hypotrophy
4. F	30/37	Domestic accident	No	FSH, LH, ACTH, TSH	Areas of hypodensity
5. F	36/53	Bicycle accident	No	ACTH, TSH, GH	Diffuse hypodensity; hypotrophy
6. F	18/29	Diving	No	FSH, LH, ACTH, TSH	Empty sella
7. F	27/52	Car accident	No	ACTH, TSH	Areas of hypodensity
8. F	58/68	Domestic accident	No	FSH, LH, TSH	Refused
9. F	18/21	Car accident	No	FSH, LH	Reduced enhancement after gadolinium injection; microcysts
10. F	22/48	Car accident	Yes	ACTH, TSH	Hypotrophy; slight dislocation of the stalk
11. F	28/29	Car accident	No	FSH, LH, TSH	Normal
12. M	11/52	Domestic accident	No	FSH, LH, ACTH, TSH	Cysts and empty sella
13. M	10/45	Bicycle accident	No	FSH, LH, ACTH, TSH	Empty sella
14. M	10/40	Domestic accident	Yes	FSH, LH, TSH	Areas of hypodensity
15. M	18/26	Motorcycle accident	Yes	FSH, LH	Diffuse hypodensity; empty sella.

^a At the time of head trauma/at our observation.

^b Cases 1–3 and 9–11 mentioned explicitly and spontaneously the head trauma. Patients 4–7, 10, and 12–15 did not.

^c Diabetes insipidus had occurred in cases 2, 6, and 10, and it was transient.

^d CT and/or MRI.

days or weeks (Fig. 2D). Of our 15 cases, none had skull fractures and only three (cases 1, 2, and 15 in Table 1) had loss of consciousness.

In brief, data in Figs. 1 and 2 illustrate most of the characteristics of the paradigmatic patients with PHTH. Such a patient is a male in his 20s who, within 1 yr from a road accident, will seek medical attention for symptoms compatible with hypopituitarism. The relatively high prevalence of females in our series is because over 80% of the patients who are referred to our Division of Endocrinology are women.

Functional Consequences

Endocrinologists use to link head trauma to one endocrine disturbance: diabetes insipidus. However, diabetes insipidus occurs only in about one of every three patients with PHTH (Fig. 3A); in our series it occurred in one of every five patients (Table 1). Thus, endocrinologists should not rely on its absence to rule out PHTH. Of the cell types present in the anterior pituitary, the gonadotrophs seem to be the most fragile because deficiency of FSH and/or LH is reported in almost 100% of the cases of PHTH. TSH or ACTH deficiency occurs in about half of the cases (44.3% or 52.8%, respectively) (Fig. 3B). In our series, TSH deficiency is higher because the vast majority of the patients referred to our Division are women who are evaluated for thyroid dysfunction. GH or PRL deficiency occurs in 23.7% or 3.8% of the cases, respectively. The integrated GH secretion is better reflected by the circulating levels of insulin-like growth factor I (IGF-I) (28). Unfortunately, serum IGF-I was measured in only 11 cases (20, 26), and in all it was normal. Of these 11 cases, serum GH was within normal limits in 10 (20). Interestingly, this study (20) found that in the deceased subgroup mean IGF-I was statistically lower than in the survived group. In our series, GH and IGF-I were subnormal in two patients (13%). Because head trauma may disturb the hypothalamic control on PRL, hyperprolactinemia has also been reported (47.7%) (Fig. 3B). This prevalence of hyperprolactinemia is in agreement with the prevalences of the pituitary stalk/hypothalamus site of

lesion based on autoptic data [45 of 106 or 42.0% (see footnote *d* of Table 2)] or imaging data [32.9% (Fig. 5)]. Quite obviously, the combinations of hormone dysfunctions are diverse. At one extreme, we can have the deficiency of all hormones and resulting generalized hypopituitarism. At the other extreme, we have selective deficiencies. Rarely, the deficiency of a given hormone may be transient. This transitoriness was observed in one of our patients (4), as well as in other cases (25, 26).

Because of the peculiar vascularization of the pituitary, the peripheral layer of anterior pituitary cells under the capsule receive arterial blood from the capsule, not from the two systems of portal veins. These cells and those in a small area near to the posterior lobe are the only surviving cells in cases of pure anterior lobe necrosis (29). The severed portal vessels can regenerate, grow down into the surviving parts of the anterior lobe, and, thus, permit some resumption of the anterior pituitary function when the site of lesion is in the pituitary. Indeed, “mytotic figures amongst the surviving cells” (29) and “unmistakably repopulated appearance of the anterior lobe” (30) have been documented. This process of revascularization and repopulation clearly requires time. Thus, it took 12 yr for a boy to recover completely from the anterior pituitary insufficiency that complicated head trauma (25). In one of our patients (4) the lag-time before resumption of the gonadotropin secretion was 10 yr from head trauma and 1 yr from normalization of the pituitary computed tomography (CT) scan (Fig. 4). The spontaneous recovery from posterior and anterior pituitary insufficiency observed 6 months after head trauma by Iglesias *et al.* (26) was very partial. In this 32-yr-old man, the cause of panhypopituitarism was a posttraumatic retention cyst that compressed and displaced pituitary (26).

Clinical Picture

This is composite, because ample is the spectrum of the possible endocrine dysfunctions (see *Functional Consequences*). In addition, hypopituitarism can be subclinical

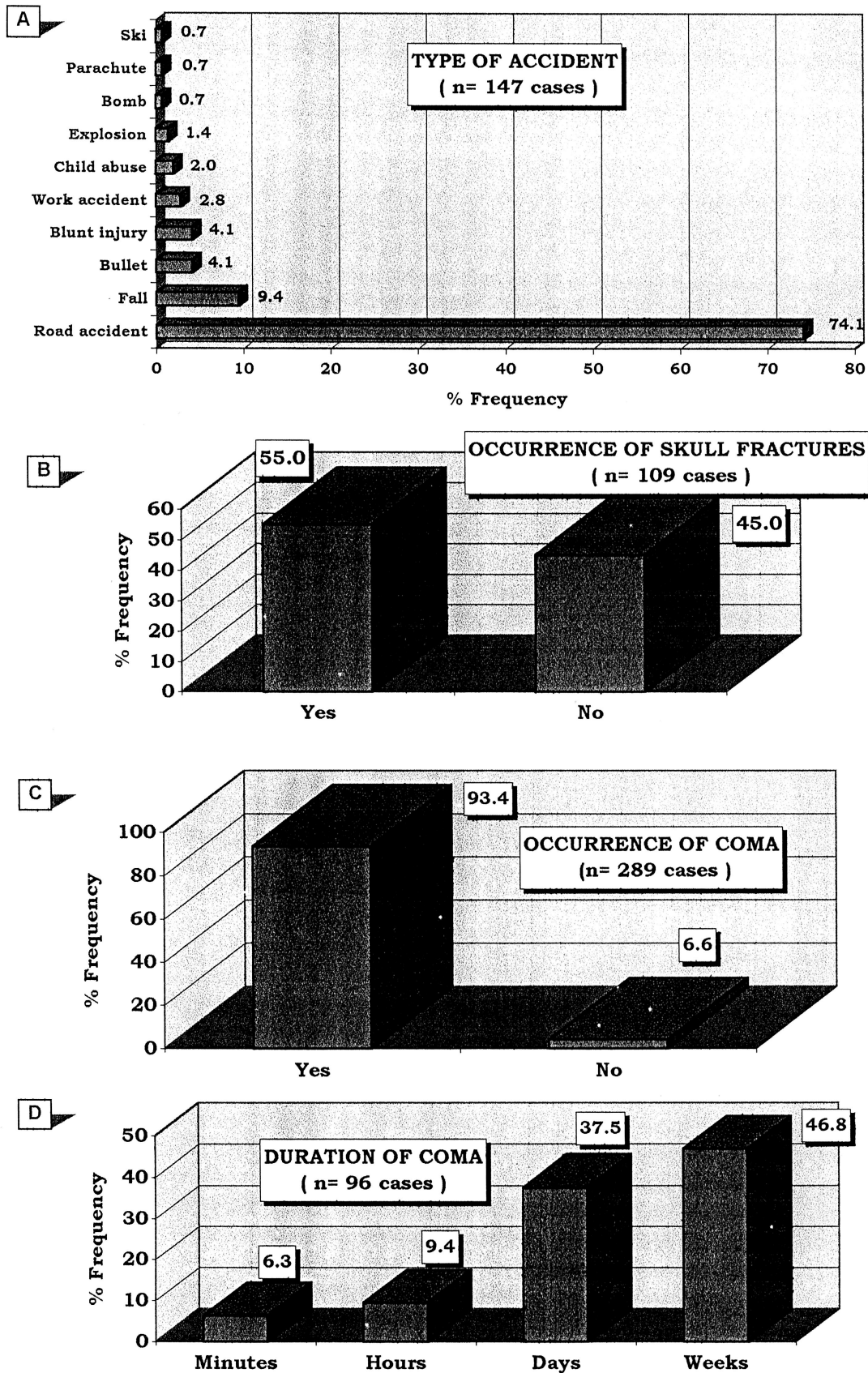


FIG. 2. Type of accident and its complications in patients with hypopituitarism secondary to head trauma.

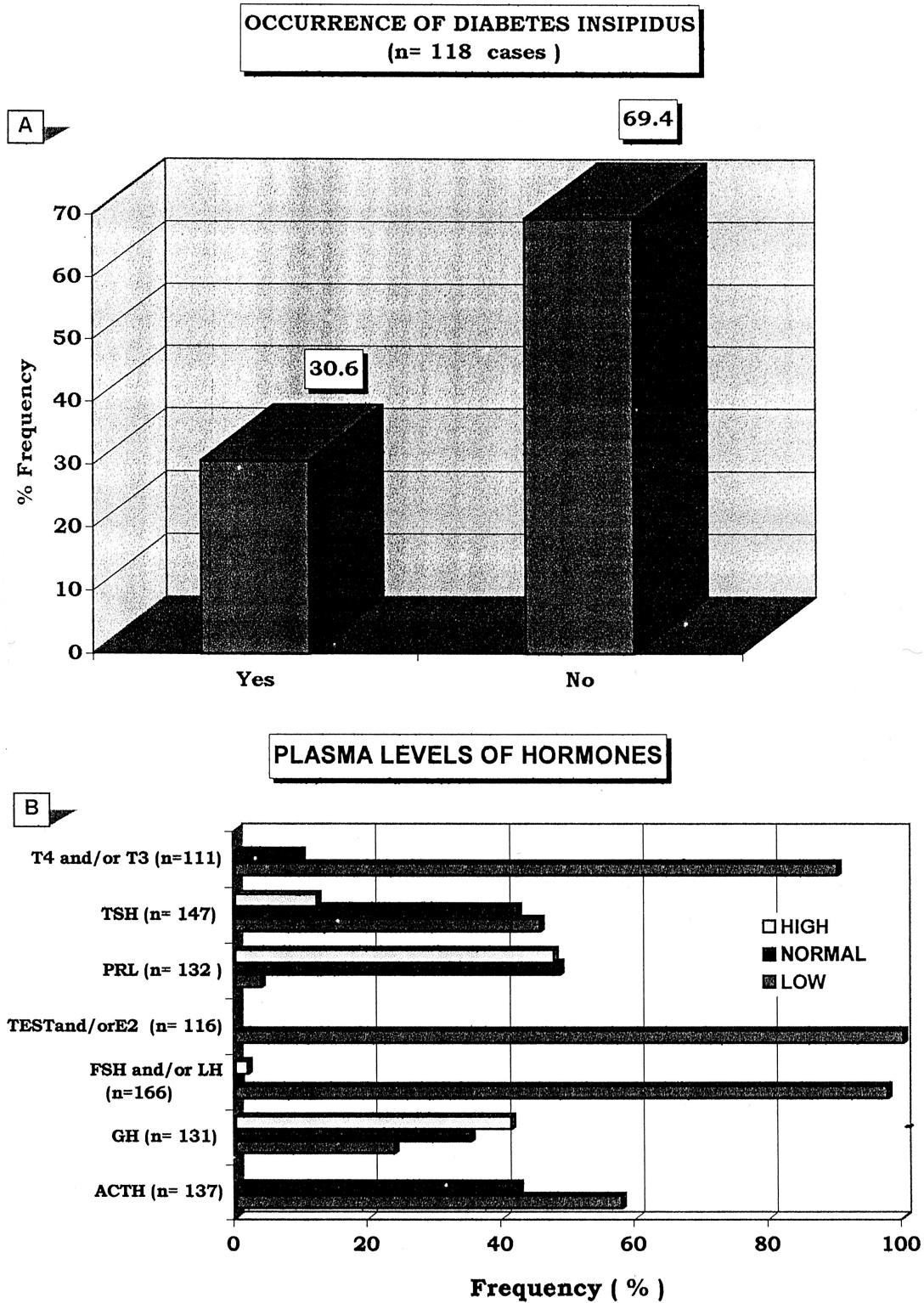


FIG. 3. Functional consequences of head trauma in patients with posttraumatic hypopituitarism.

and be revealed only by hormone measurements. The clinical onset can be quite acute and dramatic, leading the patient to the intensive care unit. Otherwise, the symptomatology, which appears first and which constitutes

the reason for seeking endocrine evaluation, is most frequently amenorrhea/infertility in women and erectile dysfunction in men. In a short letter to the editor, Cytowic and Smith (27) reported that they "found a 13% incidence

TABLE 2. Anatomical findings of the pituitary resulting from the autopsy of patients died after head trauma

	Ceballos (30) ^a (n = 102)	Kornblum and Fischer (31) ^b (n = 100)	Pierucci (32) ^c (n = 241)	Crompton (33) ^d (n = 53)
Normal	14 (13.7%)	38	110 (46%)	39 (73.6%)
Peripituitary/capsule (hemorrhage, fibrosis, thrombosis)	59 (57.8%)	59 ^e	56 (23.2%)	
Stalk				
Hemorrhage	28 (27.4%)		25 (10.3%)	
Necrosis	6 (5.9%)	6 ^f	14 (6%)	
Anterior lobe				
Hemorrhage	4 (3.9%) ^g	0	15 (6.2%)	2+0 (3.8%)
Necrosis	22 (21.6%)	22	34 (14.1%)	4+3 (13.2%)
Fibrosis	5 (4.9%)			
Posterior lobe				
Hemorrhage	20 (19.6%)	42 ^h	39 (16.2%)	4+3 (13.2%)
Necrosis	0		3 (1.2%)	
Pars intermedia				
Hemorrhage			9 (3.8%)	
Necrosis				

^a Percentages do not add up to 100% because some patients had more than one lesion. When specified (n = 70), skull fractures were absent in 33 cases (47.1%).

^b Percentage and numbers coincide because the total of patients is 100. In 62 cases, there was more than one lesion.

^c Percentages do not add up to 100% because some patients had more than one lesion.

^d This paper deals with hypothalamic lesions. However, in 53 of the 106 patients pituitary lesions were searched. These pituitary lesions occurred in 14 of 53 cases (28.0%), and precisely: 8 of 21 (38.0%) with hypothalamic lesions, 6 of 32 (19.0%) without hypothalamic lesions (In our table, the first number is for the group of the 8 patients without hypothalamic lesions and the second for the group of the patients with such lesions. Hypothalamic lesions were present in 45 of 106 cases (42.0%), and these consisted of: hemorrhage (n = 31 or 68.9%), necrosis (n = 26 or 57.8%), or both (n = 12 or 26.7%). Generally, hypothalamic lesions were associated with temporo-parietal blows and fractures of the middle fossa of the skull base.

^e Capsular hemorrhage.

^f A seventh case had laceration of the hypophyseal stalk.

^g The authors observed that this hemorrhage was most frequently an extension from stalk or posterior lobe bleeding.

^h Data given as hemorrhage and/or necrosis.

of amenorrhea in a group of 84 young women (age, 19 to 35) who had mild to moderate head injury but no permanent neurologic impairment . . . These 84 women came from a larger group of 205 consecutive patients with closed head trauma . . . Eleven women had lack of menses one to six months after trauma from a motor vehicle accident. All patients had had regular menses before the head injury . . .” Asthenia, psychic torpor, cold intolerance (because of central hypothyroidism), hypotension (because of central hypocortisolism), and galactorrhea (because of hyperprolactinemia) may be variably associated. Clearly, the symptomatology can pass undetected in a comatose patient with or without skull fractures. However, we believe that it is important to ascertain whether there is pituitary insufficiency, because: 1) hypopituitarism can be an immediate or early complication of head trauma; and 2) adrenal and/or thyroid insufficiency will contribute to maintain unconsciousness, and either one will aggravate the prognosis.

When imaging studies were performed, CT and/or magnetic resonance imaging (MRI) failed to reveal any abnormality in 5 of 76 (6.6%) cases, which is in agreement with the 1 of 13 (7.7%) frequency observed in our cases (Table 1). Such normality is higher (10 of 11) in the series reported by Cytowic and Smith (27). When lesions were detected, these were vascular insults of the pituitary in half the cases (Fig. 5).

Pathology

Autopsy studies (30-33) are summarized in Table 2. The six cases reported by Daniel *et al.* (29) are omitted from this

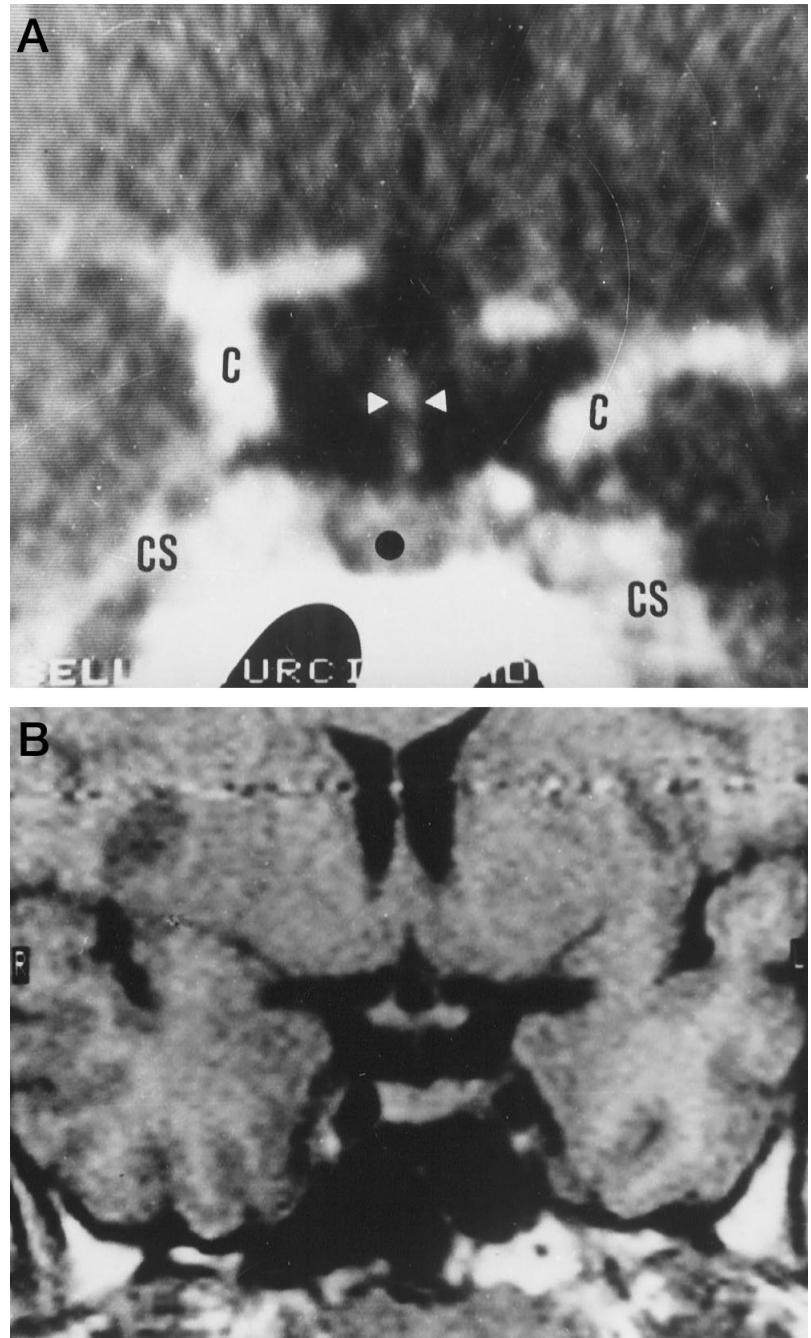
table because the authors did not specify whether these cases of traumatic necrosis of the pituitary anterior lobe were sporadic cases or, instead, were part of a large series of unspecified size. Patients had died “soon after” head trauma (32), after “immediate or remote” head trauma (30), or after an unspecified period of time since trauma (31, 33). The circumstances of trauma were diverse, and hormone measurements before death were unavailable. A comparison among such studies is difficult because of the different size of the series and the concurrence of more than one lesion.

Disagreements between studies are evident (Table 2). For instance, the anatomical integrity of the pituitary varies from 14% (30) to 74% (33); certain lesions, such as anterior pituitary fibrosis or hemorrhage of pars intermedia, are mentioned only by some authors (32). On the other hand, certain other lesions, such as the necrosis of the pituitary stalk, are found with exactly the same frequency (6%) (30-32). Other differences are evident when correlations with death (data not given in Table 1) were searched (30, 31). For instance, peripituitary/capsule lesions were observed more frequently in patients who died within 2 days after trauma (30) or any time since trauma (31). Concerning necrosis of the anterior lobe, instead, both studies (30, 31) agree that it is more frequent in patients who died within 1 week since trauma.

Final Considerations

Pituitary insufficiency can have life-threatening consequences. Hypopituitarism impairs adaptation to stressful events and represents a negative risk factor for the prognosis of the traumatized patient. PHTH, the characteristics

FIG. 4. CT scan of one patient (case 15 in Table 1) with posttraumatic hypopituitarism. *Top*, Coronal slice of the sella turcica after contrast injection. Note that: 1) pituitary stalk is regular (*white arrowheads*); 2) the upper profile of the pituitary gland is normally concave; and 3) the pituitary parenchyma is diffusely hypodense (*black dot*). An early/partial empty sella is apparent. C, Internal carotid; CS, cavernous sinus. *Bottom*, Repetition of the CT scan 1 yr later. Density of the pituitary is virtually normal, partial empty sella is still present (from Ref. 4, with permission of the authors and the *Journal of Endocrinological Investigation*).



of which can be summarized as in Table 3, is certainly less rare than commonly believed. Among the reasons why it can escape diagnosis, two seem to be prominent. First, the trauma may have occurred decades earlier and may also have been forgotten. This is more likely to occur when trauma was domestic, not followed by hospitalization and/or not complicated by skull fractures, loss of consciousness, or diabetes insipidus. Second, there could be lack of insistence by the endocrinologist to ask specifically for past head traumas to both the patient and his or her relatives. Of 100 endocrinologists we have inquired (unpublished data), all would associate PHTH to a complicated head trauma occurred within "days" to a "couple of

years" from trauma, but none would think of interrogating the relatives. Approximately four of five endocrinologists would not consider the possibility of PHTH, should a patient with no history of posttraumatic diabetes insipidus seek consultation for symptoms compatible with pituitary insufficiency (amenorrhea, asthenia, and so on). Thus, chances are that PHTH is underdiagnosed whereas idiopathic hypopituitarism is overdiagnosed.

The question then arises whether a patient who had suffered a head trauma needs to be followed up over time. Because long-term longitudinal studies on this issue have not been performed, we lack well-grounded answers to offer. A practical approach could be the "3/4 rule" because: 1) about

ANATOMIC LESIONS OF THE PITUITARY, STALK AND HYPOTHALAMUS AT CT/MRI (n= 76)

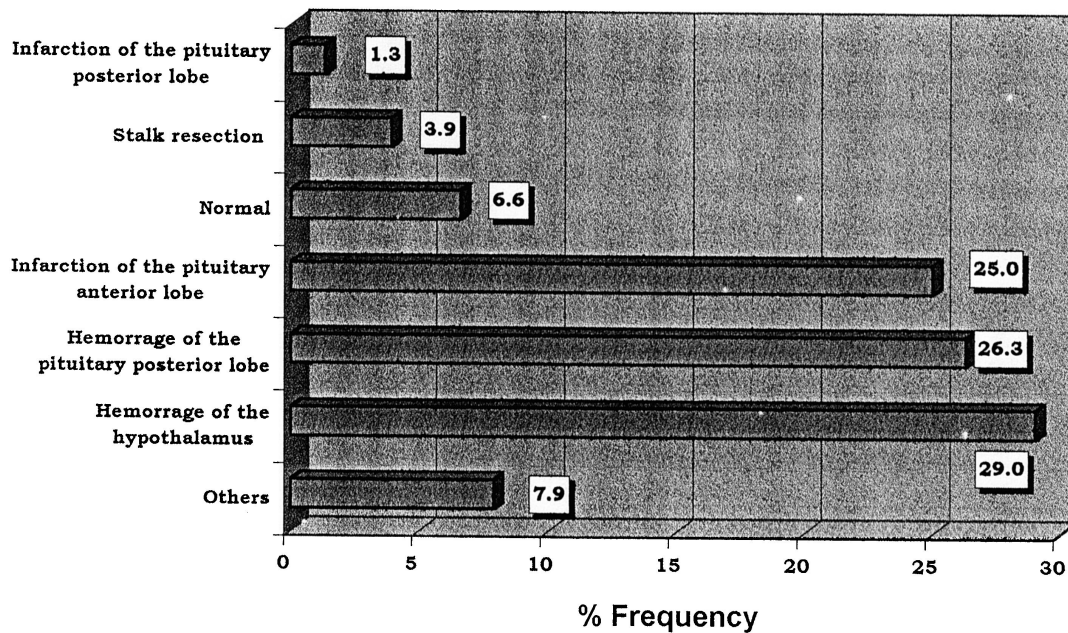


FIG. 5. Anatomic lesions demonstrated by CT or MRI in patients with posttraumatic hypopituitarism.

TABLE 3. Summary of the relevant data of the literature on posttraumatic hypopituitarism

Male to female ratio	~5:1
Age at trauma (decade most affected)	20–29 yr, accounting for 35.3% of the cases
Time elapsed between trauma and diagnosis	
Range	Few days to >40 yr
Rate	71.0% soon after or <1 yr from trauma; 29.0% at an average rate of ~3% per yr.
Most frequent type of trauma	Road accident (74.1%)
Occurrence of skull fracture	55.0%
Occurrence of coma/unconsciousness	93.4%
Most frequent duration of coma	Days to weeks
Most frequent type of anatomical lesions (CT/MRI)	
Hemorrhage of the hypothalamus	29.0%
Hemorrhage of the pituitary posterior lobe	26.3%
Occurrence of diabetes insipidus	30.6%

¾ of PHTH patients are males 40 yr of age or less (at the time of trauma); 2) about ¾ of PHTH causes are road accidents; and 3) PHTH occurs within 1 yr in three fourths of cases. A patient who meets these criteria is a good candidate to target for the follow-up (*i.e.* he is the one in whom PHTH will occur with the highest likelihood). Follow-up can also have forensic implications. This is an issue that has never been ap-

proached before. These practical situations may develop: 1) PHTH is considered, then is excluded, but eventually it develops several years later; and 2) PHTH is diagnosed and recognized as a damage to be paid, but after a number of years there is a spontaneous recovery due to pituitary revascularization and repopulation.

In conclusion, physicians should be more alerted about PHTH, particularly in the patients most at risk.

References

- Escamilla RF, Lissner H. 1942 Simmonds disease. *J Clin Endocrinol.* 2:65–96.
- Altman R, Pruzanski W. 1961 Post-traumatic hypopituitarism. *Ann Intern Med.* 55:149–154.
- Edwards OM, Clark JDA. 1986 Post-traumatic hypopituitarism. Six cases and review of the literature. *Medicine (Baltimore).* 65:281–290.
- Benvenega S, Lo Giudice F, Campenni A, Longo M, Trimarchi F. 1997 Post-traumatic selective hypogonadotropic hypogonadism. *J Endocrinol Invest.* 20:675–680.
- Benvenega S, Lo Giudice F, Campenni A, Ruggeri RM, Trimarchi F. Central hypothyroidism due to head trauma. *Proceedings of the 81st Annual Meeting of The Endocrine Society, San Diego, CA, 1999 (Abstract P2-433).*
- Rudman D, Fleischer AS, Kutner MH, Raggio JF. 1977 Suprahypophyseal hypogonadism and hypothyroidism during prolonged coma and head trauma. *J Clin Endocrinol Metab.* 45:747–753.
- Fleischer AS, Rudman DR, Payne NS, Tindall GT. 1978 Hypothalamic hypothyroidism and hypogonadism in prolonged traumatic coma. *J Neurosurg.* 49:650–657.
- King LR, Knowles HC, McLaurin RL, Brielmaier J, Perisutti G, Piziak VK. 1981 Pituitary hormone response to head injury. *Neurosurgery.* 9:229–235.
- Fernandez Castaner M, Ayma Sola J, Martinez de Osaba MJ, Vilardell E. 1981 Diabetes insipida e hipopituitarismo postraumaticos. *Consideraciones diagnosticas a proposito de tres casos.* *Med Clin (Barcelona).* 78:358–362.
- Holness RO, Ogundimu FA, Langille RA. 1983 Pituitary apoplexy following closed head trauma. *J Neurosurg.* 59:677–679.
- Maisey DN, Mills IH, Middleton H, Williams IG. 1984 A case of Klinefelter's syndrome with acquired hypopituitarism. *Acta Endocrinol.* 105:126–129.
- Nuno Alvarez E, Benito Lopez P, Perez Jimenez F, Jimenez Pereperez A. 1985

- Hypopituitarismo hipotalámico postraumático: secreción alterada de TSH por falta de modulación dopaminérgica. *Med Clin*. 85:556–557.
13. **Woolf PD, Hamill RW, McDonald JV, Lee LA, Kelly M.** 1985 Transient hypogonadotropic hypogonadism caused by critical illness. *J Clin Endocrinol Metab*. 60:444–450.
 14. **Woolf PD, Hamill RW, McDonald JV, Lee LA, Kelly M.** 1986 Transient hypogonadotropic hypogonadism after head trauma: effects on steroid precursors and correlation with sympathetic nervous system activity. *Clin Endocrinol*. 25:265–274.
 15. **Moussalli C, Adler RA.** 1986 Hypothalamic dysfunction from stab wound. *Mil Med*. 151:120–122.
 16. **Massol J, Humbert PH, Cattin F, Bonneville JF.** 1987 Post-traumatic diabetes insipidus and amenorrhea-galactorrhea syndrome after pituitary stalk rupture. *Neuroradiology*. 29:299–300.
 17. **Chiolero R, Lemarchand TH, Schutz Y, et al.** 1988 Plasma pituitary hormone levels in severe trauma with or without head injury. *J Trauma*. 28:1368–1374.
 18. **Clark JDA, Raggatt PR, Edwards OM.** 1988 Hypothalamic hypogonadism following major head injury. *Clin Endocrinol*. 29:153–165.
 19. **Lim HS, Ang BK, Ngim RCK.** 1990 Hypopituitarism following head injury—a case report. *Ann Acad Med Singapore*. 19:851–856.
 20. **Gottardis M, Nigitsch C, Schmutzhard, et al.** 1990 The secretion of human growth hormone stimulated by human growth hormone releasing factor following severe cranio-cerebral trauma. *Intensive Care Med*. 16:163–166.
 21. **Xiao-ping Z, Meng-yao Z, Yi-zhen J, Zong-nan G, Ling-shan K.** 1990 Dynamic observation on thyroid function in severe head injury. *Chin Med J*. 103:335–338.
 22. **Gunn IR, Beastall GH, Matthews DM, Bath JCJL.** 1991 Post-traumatic hypothalamic-pituitary dysfunction presenting with biochemical features of primary hypothyroidism. *Ann Clin Biochem*. 28:327–330.
 23. **Majhi D, Maity B, Chakraborty I, Roy I.** 1993 Post-traumatic hypopituitarism. *J Indian Med Assoc*. 91:261–262.
 24. **Mariani R, Bortoluzzi MN, Richelme C, El Barbary M, Coussement A.** 1996 Hypopituitarisme post-traumatisme crânien: a propos de trois cas. *Arch Pediatr*. 3:796–801.
 25. **Eiholzer U, Zachmann M, Gnehm H.E, Prader A.** 1986 Recovery from post-traumatic anterior pituitary insufficiency. *Eur J Pediatr*. 145:128–130.
 26. **Iglesias P, Gomez-Pan A, Diez JJ.** 1996 Spontaneous recovery from post-traumatic hypopituitarism. *J Endocrinol Invest*. 19:320–323.
 27. **Cytowic RE, Smith A.** 1986 Transient amenorrhea after closed head trauma (Letter). *N Engl J Med*. 314:715.
 28. **Giustina A, Veldhuis JD.** 1998 Pathophysiology of the neuroregulation of growth hormone secretion in experimental animals and the human. *Endocr Rev*. 19:717–797.
 29. **Daniel PM, Prichard MML, Triep CS.** 1959 Traumatic infarction of the anterior lobe of the pituitary gland. *Lancet*. 2:927–930.
 30. **Ceballos R.** 1966 Pituitary changes in head trauma. Analysis of 102 consecutive cases of head injury. *Ala J Med Sci*. 3:185–198.
 31. **Kornblum RN, Fisher RS.** 1969 Pituitary lesions in craniocerebral injuries. *Arch Pathol*. 88:242–248.
 32. **Pierucci G, Gherson G, Tavani M.** 1971 Alterazioni ipofisarie-in particolare necrotiche-a seguito di traumi cranio-encefalici. *Pathologica*. 63:71–88.
 33. **Crompton MR.** 1971 Hypothalamic lesions following closed head injury. *Brain*. 94:165–172.